



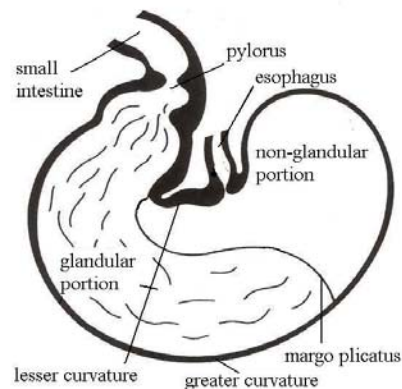
September 2006

## Previous VET NOTES

- Rhodococcal pneumonia - August 2006
- Managing limb deformities in foal with dynaslplints - July 2006
- Disaster preparedness - June 2006
- Mare reproductive loss syndrome (MRLS) - May 2006
- April 2006 - Exercise-induced pulmonary hemorrhage
- March 2006 - The use of high speed treadmill to diagnose upper respiratory tract disorders
- February 2006 - Common medications used to assist breeding, cycle regulation and pregnancy maintenance of the mare
- January 2006 - Managing high risk pregnancies
- December 2005 - Affording the unhealthy horse
- November 2005 - Strangles
- October 2005 - The "dummy" foal
- September 2005 - New medications
- August 2005 - Extracorporeal shockwave therapy (ESWT)
- July 2005 - Vaccination recommendations
- June 2005 - The advantages of high fat/low carbohydrate diets for horses

## Gastroscopy

The equine stomach is divided into two portions; it is lined dorsally by stratified squamous epithelium (non-glandular) and ventrally by glandular epithelium. The division between these two portions is the margo plicatus. The non-glandular portion of the stomach essentially functions as a reservoir for food and has no secretory or absorptive function. The glandular portion of the stomach is similar to the lining of the stomach of humans and some other animals. This portion secretes hydrochloric acid, pepsin, electrolytes, and water. The glandular lining contains a mucus/ bicarbonate barrier that protects itself from the acidic environment and has growth factors that promote mucosal healing. The non-glandular lining, on the other hand, does not have any protection from acidic injury. Eating stimulates secretion of bicarbonate-rich saliva that helps neutralize gastric acid, and the roughage itself absorbs the secretions. These are the only defense mechanisms for the non-glandular epithelium. Hydrochloric acid is continuously secreted from the stomach, even when the horse is not eating. If food is withheld from a horse, lesions can develop in the non-glandular mucosa within 24-48 hours due to the contact with hydrochloric acid.



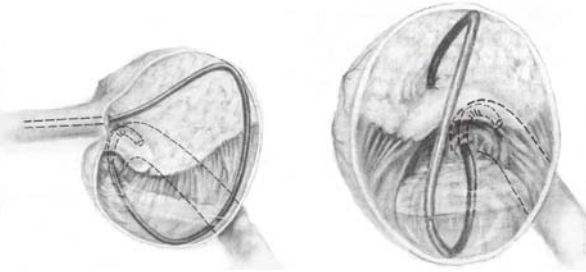
Gastric ulceration is the most common disorder of the equine stomach. It is influenced by the management and use of the horse. The occurrence of ulcers has been reported as high as 60% in show horses and as high as 90% in racehorses. Horses turned out onto pasture and exercised lightly typically have normal stomachs or only very mild erosions. In contrast, horses kept in box stalls and trained intensively have a high occurrence of significant gastric lesions. It has been shown that the severity of the lesions corresponds with the intensity of exercise. Stress, such as hauling and mixing groups of horses, can increase the likelihood of ulcers. Furthermore, restricting access to roughage or feeding a large amount of concentrate promotes increased acidity of the stomach, thereby damaging the non-glandular mucosa.

Signs of gastric ulceration can be vague and non-specific. These horses may show abdominal discomfort, indicated by mild-to-moderate colic and frequent laying down. They may also have poor appetite, poor body condition, poor hair coat, attitude changes, and decreased performance. The severity of these signs does not indicate the severity of the lesions. Horses with superficial erosions may have significant discomfort, whereas horses with deep, bleeding ulcers may have mild clinical signs.

(Continued on page 2)

**Christina M. Ellis, DVM**

Gastrosocopy is the only method of definitively diagnosing gastric ulceration. A 3-meter endoscope is passed into the nostril and down the esophagus into the stomach for visualization of the gastric mucosa. Most lesions are identified in the non-glandular mucosa, adjacent to the margo plicatus along the right side or the lesser curvature of the stomach. More severe cases may have larger ulcerations extending dorsally, towards the top of the stomach. Lesions are rarely identified in the glandular portion of the adult equine stomach. Glandular lesions can form due to administration of nonsteroidal anti-inflammatory medications (phenylbutazone [Bute], flunixin meglumine [Banamine]). These medications compromise the protective mechanisms of the gastric mucosa, leading to ulceration.



A variety of medications are available for treatment of gastric ulcers. Decisions on which medications to use depend on the location of the lesions, the severity of the lesions, and the financial constraints of the owner. The best treatment is proton pump inhibitors, such as omeprazole (Gastrogard) and lansoprazole. This class of drug binds to the proton pump and inhibits the secretion of hydrochloric acid. It has proven very effective in healing gastric ulcers, including horses that remain in race training. It is available as a paste and only needs to be administered once daily. The next class of medication is histamine type-2 receptor antagonists. This includes ranitidine (Zantac), cimetidine (Tagament), and famotidine (Pepcid). These drugs bind to the receptors on the gastric cells, and also inhibit secretion of hydrochloric acid by a different mechanism than proton pump inhibitors. They reduce gastric acidity for 1-8 hours, and are therefore dosed for administration three times daily. There is variability among horses in the magnitude and effect of this drug, which makes its effectiveness less predictable. When effective, however, these drugs are significantly cheaper than proton pump inhibitors. Another class of drugs is antacids, such as magnesium oxide and aluminum hydroxide (Maalox, Mylanta). Antacids neutralize gastric acid but only for a brief period of time (30-120 minutes) and need to be given in large volumes to be effective. Thus, antacids are not a practical treatment option. Finally, sucralfate, a mucosal adherent, is unique in that it is beneficial for treatment of glandular ulcers. Sucralfate acts as a "band-aid" and binds to the gastric glandular mucosa. It enhances mucus production, mucosal prostaglandin synthesis, and mucosal blood flow. Sucralfate is not recommended for the typical adult horse with non-glandular gastric ulcers and should be reserved for horses with glandular lesions.

The ideal preventative measure for gastric ulcer formation is to cease exercise training and turn the horse out onto pasture. However, this is not feasible in most situations. Some horses appear to develop ulcers more readily than others, and these horses are more likely to have recurrence after successful treatment. Feeding management can be modified to promote more continuous roughage consumption and less concentrate consumption, which will help reduce the gastric acidity. It has been suggested that alfalfa hay is superior to grass hay for prevention of ulcers due to the high protein content, which may buffer the acidic environment. Recently, omeprazole has been dosed for prevention of gastric ulcers and marketed under the name Ulcergard. It has been found to be effective at prevention of gastric ulcers in horses undergoing intensive race training, whereas other treatments such as ranitidine have shown to be ineffective in these cases.

Horses suspected of gastric ulcers can be easily diagnosed with gastrosocopy and effective treatment can be initiated. Performing repeat gastrosocopies are beneficial to assess the effectiveness of the treatment and the progression of healing. Once the lesions are healed, measures should be taken to prevent recurrence.

- May 2005 - The Hoof: Form and function
- March 2005 - Liquid gold
- February 2005 - Breeding the problem mare
- January 2005 - Condylar fractures
- December 2004 - Early diagnosis and treatment of high-risk pregnancy in the mare
- November 2004 - Know your horse
- October 2004 - White Line Disease
- September 2004 - Announcements
- August 2004 - Reminders for pregnant mare management
- July 2004 - The heat is on
- June 2004 - Equine first aid

We're on the web:  
[www.petersonsmith.com](http://www.petersonsmith.com)



4747 SW 60th Avenue  
 Ocala, FL 34474

Phone: (352) 237-6151  
 Fax: (352) 237-0629  
 Email: [PSEH@petersonsmith.com](mailto:PSEH@petersonsmith.com)

*A Tradition of Leadership and  
 Excellence in Equine Medicine*